

# Appreciation of Postpartum Changes of the Rectus Muscles in Primary and Repeated Abdominoplasty

Lindsay E. Janes, M.D.  
Megan E. Fracol, M.D.  
Gregory A. Dumanian, M.D.

Chicago, Ill.



**Background:** Abdominoplasty is one of the top five most commonly performed cosmetic procedures. Whereas widening of the linea alba is a well-accepted consequence of pregnancy, the changes to the rectus abdominis muscles are less well known and thus unappreciated and undertreated.

**Methods:** After institutional review board approval, the Northwestern Enterprise Data Warehouse identified nulliparous and multiparous women, aged 18 to 45 years, who underwent abdominal computed tomography between 2000 and the present. Measurements included the width and cross-sectional area of each rectus muscle, width of the linea alba, and circumference of the abdominal cavity at the level of the L3 vertebra. In addition, two case reports addressing these anatomical changes with muscle modification and mesh reinforcement are presented.

**Results:** Sixty women were identified that met our inclusion criteria: 15 nulliparous, 15 after one pregnancy (para 1), 15 after two pregnancies (para 2), and 15 after three or more pregnancies (para  $\geq 3$ ). The linea alba was significantly widened after one pregnancy from 1.14 cm to 2.29 cm, but did not significantly widen further with each subsequent pregnancy. The width of each rectus muscle was significantly widened from  $6.00 \pm 0.60$  cm in nulliparous to  $6.61 \pm 0.58$  cm in para 1, significantly widened again to  $7.03 \pm 0.46$  cm in para 2, but not significantly widened after that ( $6.97 \pm 1.00$  cm in para 3).

**Conclusions:** In addition to widening of the linea alba, pregnancy alters the shape of the rectus abdominis muscle. Correction of muscle width during abdominoplasty may be a necessary adjunct to achieve the proper tension in both primary and revision procedures. (*Plast. Reconstr. Surg.* 144: 197e, 2019.)

**CLINICAL QUESTION/LEVEL OF EVIDENCE:** Therapeutic, V.

In 2017, almost 130,000 abdominoplasties were performed in the United States.<sup>1</sup> However, patient dissatisfaction remains common, with the rate of secondary abdominoplasty ranging from 7 to 26 percent.<sup>2,3</sup> Although recurrent skin laxity is straightforward in its cause and remedy, persistent abdominal wall bulging is less commonly described and can lead to dramatic patient dissatisfaction and discomfort. Several patients dissatisfied with their standard abdominoplasties were noted by computed tomography to have adequate approximation of the medial border of their rectus muscles and a well-plicated linea alba, but to still have a persistent “floppy

abdomen” on examination. It was these patients and their outcomes that led to the following study to determine baseline measurements of the rectus muscles and linea alba, and the changes to these structures with pregnancy. Our hypothesis

**Disclosure:** Dr. Dumanian holds intellectual property in the Advanced Suture Inc. and the Mesh Suture Inc. None of the authors has any relevant disclosures of conflict of interest for this article.

Supplemental digital content is available for this article. Direct URL citations appear in the text; simply type the URL address into any Web browser to access this content. Clickable links to the material are provided in the HTML text of this article on the *Journal's* website (www.PRSJournal.com).

From the Division of Plastic Surgery, Department of Surgery, Northwestern Feinberg School of Medicine.

Received for publication August 26, 2018; accepted February 5, 2019.

Copyright © 2019 by the American Society of Plastic Surgeons

DOI: 10.1097/PRS.0000000000005862

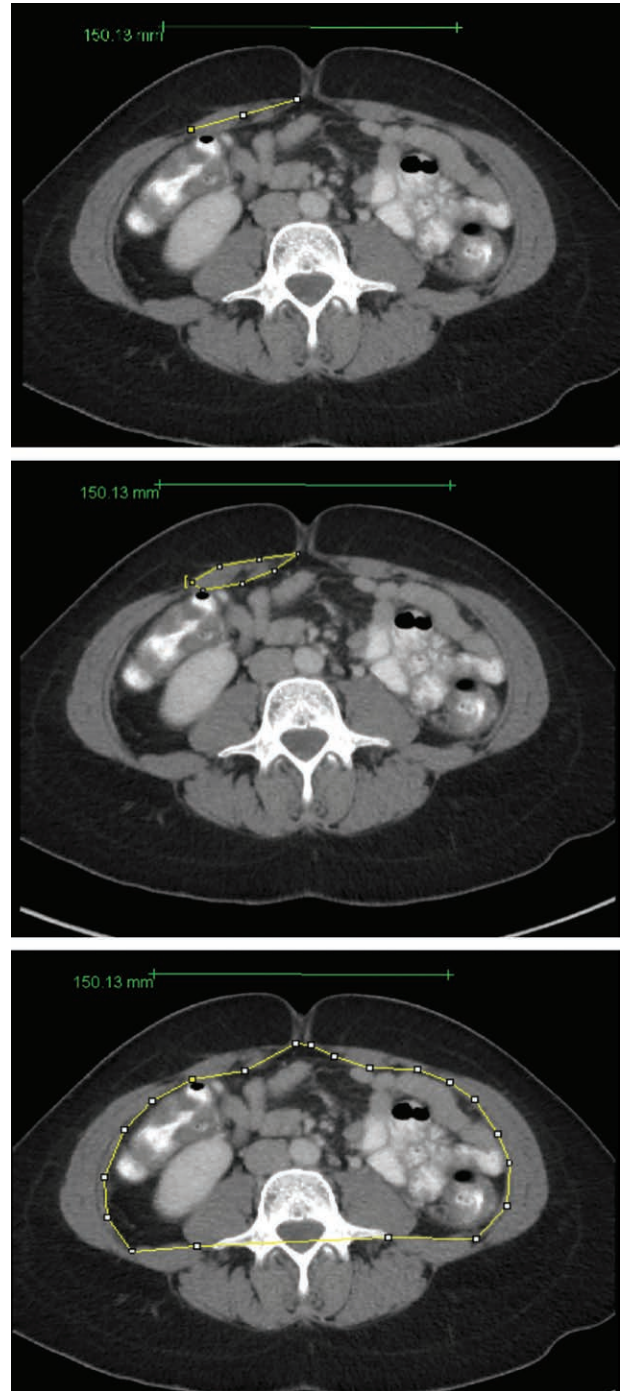is that an improved understanding of baseline anatomical variables of the abdominal wall may lead to improved diagnosis and altered operations for these patients.

### PATIENTS AND METHODS

After institutional review board approval, the Northwestern Enterprise Data Warehouse identified pools of nulliparous and multiparous women who underwent abdominal computed tomography. Inclusion criteria included the following: women aged 18 to 45 years who underwent abdominal computed tomography between 2000 and 2017. Exclusion criteria included the following: hernias present at the time of computed tomography; prior major abdominal surgery; body mass index less than 18 or greater than 30 kg/m<sup>2</sup>, which was documented within 6 months of computed tomography; or complicating underlying medical problems such as cirrhosis. Major abdominal surgery was defined as any procedure requiring a laparotomy or open incision; women who underwent uncomplicated laparoscopic surgery for appendectomy or cholecystectomy were not excluded. In addition, for multiparous women, the computed tomographic scan must have been completed at least 1 year after delivery to allow recoil of tissues. Centricity Universal Viewer (GE Healthcare, Chicago, Ill.) was used to view scans and save an axial periumbilical image at the L3 vertebrae (approximately the level of umbilicus). The images were processed using ImageJ software (National Institutes of Health, Bethesda, Md.). Measurements included the width of each rectus muscle, width of the rectus diastasis, circumference of the abdominal cavity, and cross-sectional area of each rectus muscle (Fig. 1). Measurements were performed independently by two researchers; any measurements with a greater than 5 percent difference were remeasured by the researchers independently to confirm measurements. All measurements were then averaged. The sum of the rectus widths was divided by the total abdominal circumference to control for patient size variability. One-way analysis of variance with Fisher's multiple comparison test was performed using GraphPad Prism, version 7.02 for Windows (GraphPad Software, Inc., La Jolla, Calif.).

### RESULTS

Sixty women were identified that met our inclusion criteria: 15 nulliparous, 15 after one pregnancy (para 1), 15 after two pregnancies (para 2),



**Fig. 1.** Measurements were performed using ImageJ software. Measurements included the width of each rectus muscle (*top*), the cross sectional area of each rectus muscle (*center*) and the intraabdominal circumference (*bottom*).

and 15 after three or more pregnancies (para  $\geq 3$ ). The linea alba was significantly widened after one pregnancy (1.14 cm versus 2.29 cm;  $p = 0.0006$ ) but did not significantly widen further with each subsequent pregnancy. The width of each rectus muscle was significantly widened from 6.00

**Table 1. Analysis of Variance with Fisher’s Multiple Comparison Test\***

|   | Nulliparous | Para 1       |          | Para 2       |          | Para 3       |          |
|---|-------------|--------------|----------|--------------|----------|--------------|----------|
|   |             | Value        | <i>p</i> | Value        | <i>p</i> | Value        | <i>p</i> |
| Rectus diastasis, cm                      | 1.14 ± 0.46 | 2.29 ± 0.83† | 0.0006   | 2.22 ± 0.93‡ | 0.85     | 2.50 ± 1.11‡ | 0.39     |
| Rectus width, cm                          | 6.00 ± 0.6  | 6.6 ± 0.58†  | 0.001    | 7.03 ± 0.46§ | 0.02     | 6.97 ± 1.04‡ | 0.72     |
| Total rectus width-to-circumference ratio | 0.22 ± 2.51 | 0.23 ± 1.20§ | 0.037    | 0.25 ± 1.22§ | 0.02     | 0.24 ± 1.89‡ | 0.23     |
| Rectus CSA, cm <sup>2</sup>               | 5.3 ± 0.78  | 5.08 ± 1.02‡ | 0.58     | 5.12 ± 0.56‡ | 0.92     | 5.10 ± 1.51‡ | 0.96     |

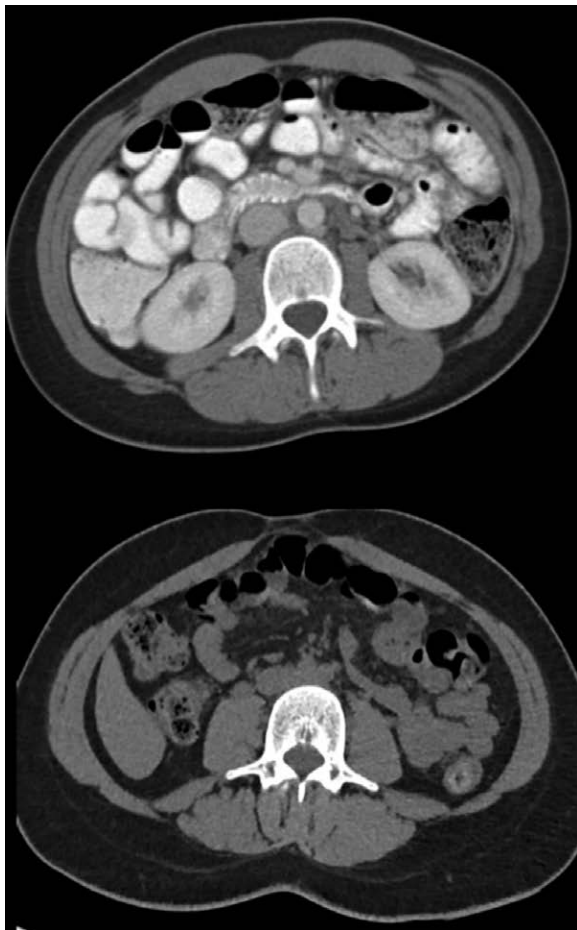CSA, cross-sectional area.

\*The *p* values compare each group to the previous: nulliparous versus para 1, para 1 versus para 2, para 2 versus para 3.

†*p* < 0.001.

‡Not significant.

§*p* < 0.05.



**Fig. 2.** Representative images of computed tomographic scan of a nulliparous woman compared to para 2. Note the characteristic postpartum shape change.

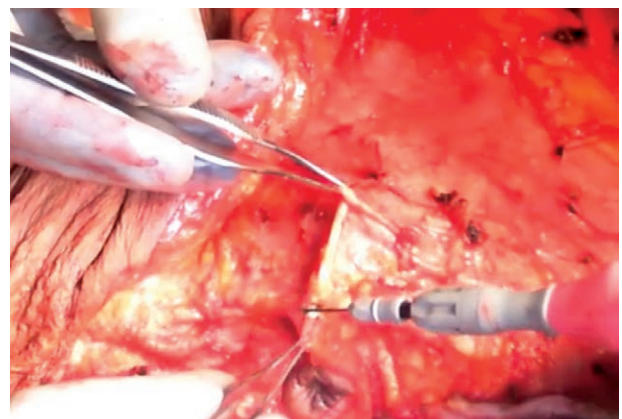
± 0.60 cm to 6.61 ± 0.58 cm; *p* = 0.001) after one pregnancy and then significantly widened again to 7.03 ± 0.46 cm (*p* = 0.02) after an additional pregnancy. However, the muscles did not significantly widen further between the second and subsequent pregnancies (7.03 ± 0.46 cm to 6.97 ± 1.04 cm; *p* = 0.72). This finding remained consistent when we controlled for total abdominal circumference

(total rectus width/circumference). Pregnancy did not cause atrophy of the muscle, as the cross-sectional area was not significantly different across groups (Table 1 and Fig. 2).

### CASE REPORTS

#### Case 1

A 36-year-old woman (gravida 3, para 3) presented with significant skin laxity and abdominal bulging, seeking an abdominoplasty (Fig. 3, *above*). Her preoperative examination demonstrates approximately 3 to 4 cm of rectus diastasis and highlights the significant loss of core strength, as she struggles to perform a sit-up without the assistance of her arms. She underwent mesh abdominoplasty as described in a prior report,<sup>4</sup> with resection of approximately 3.5 cm of medial rectus abdominis bilaterally and placement of an 8-cm-wide soft Prolene (Ethicon, Inc., Somerville, N.J.) mesh in a retrorectus position with the muscles medialized by transrectus abdominis sutures. The patient recovered well and remains happy with her result 18 months postoperatively (Fig. 3, *below*). Her postoperative



**Video Available Online**

**Video.** Supplemental Digital Content 1, which demonstrates mesh abdominoplasty with medial resection of rectus muscle along with preoperative and postoperative examinations, is available in the “Related Videos” section of the full-text article on PRSJournals.com or, for Ovid users, at <http://links.lww.com/PRS/D560>.



examination demonstrates an intact abdominal wall reconstruction at 18 months and a flat contour. (See Video, Supplemental Digital Content 1, which demonstrates mesh abdominoplasty with medial resection of rectus muscle along with preoperative and postoperative examinations, available in the “Related Videos” section of the full-text article on PRSJJournal.com or, for Ovid users, at <http://links.lww.com/PRS/D560>.)

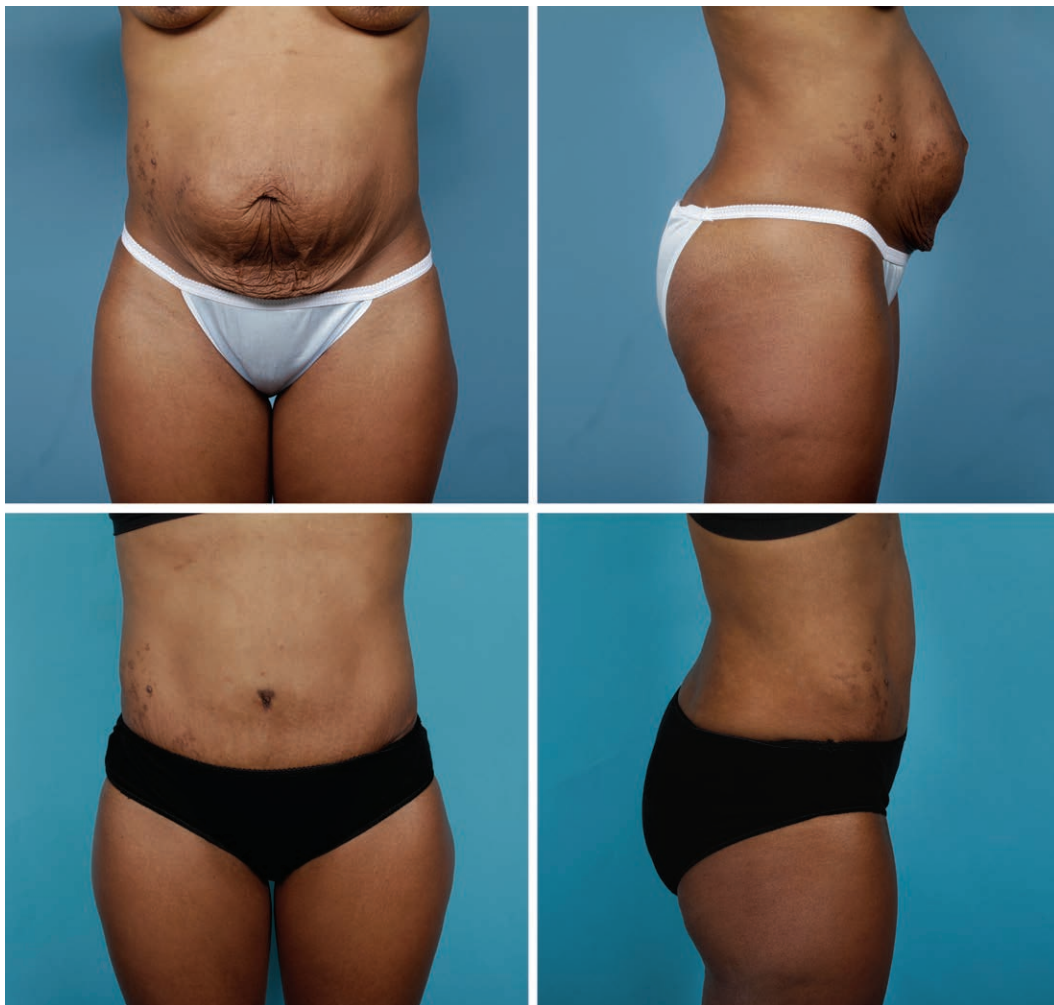## Case 2

A 38-year-old woman (gravida 2, para 2) presented with a history of two abdominoplasty procedures performed at another institution. In the first procedure, a 1-cm incisional hernia was repaired with braided polyester suture, followed by supraumbilical and infraumbilical plication of a marked rectus diastasis with additional sutures. The operative note also reports placement of several lateral sutures for improved tightening. In the second procedure, the outside operative report describes plication of the abdomen in multiple layers with polypropylene suture,

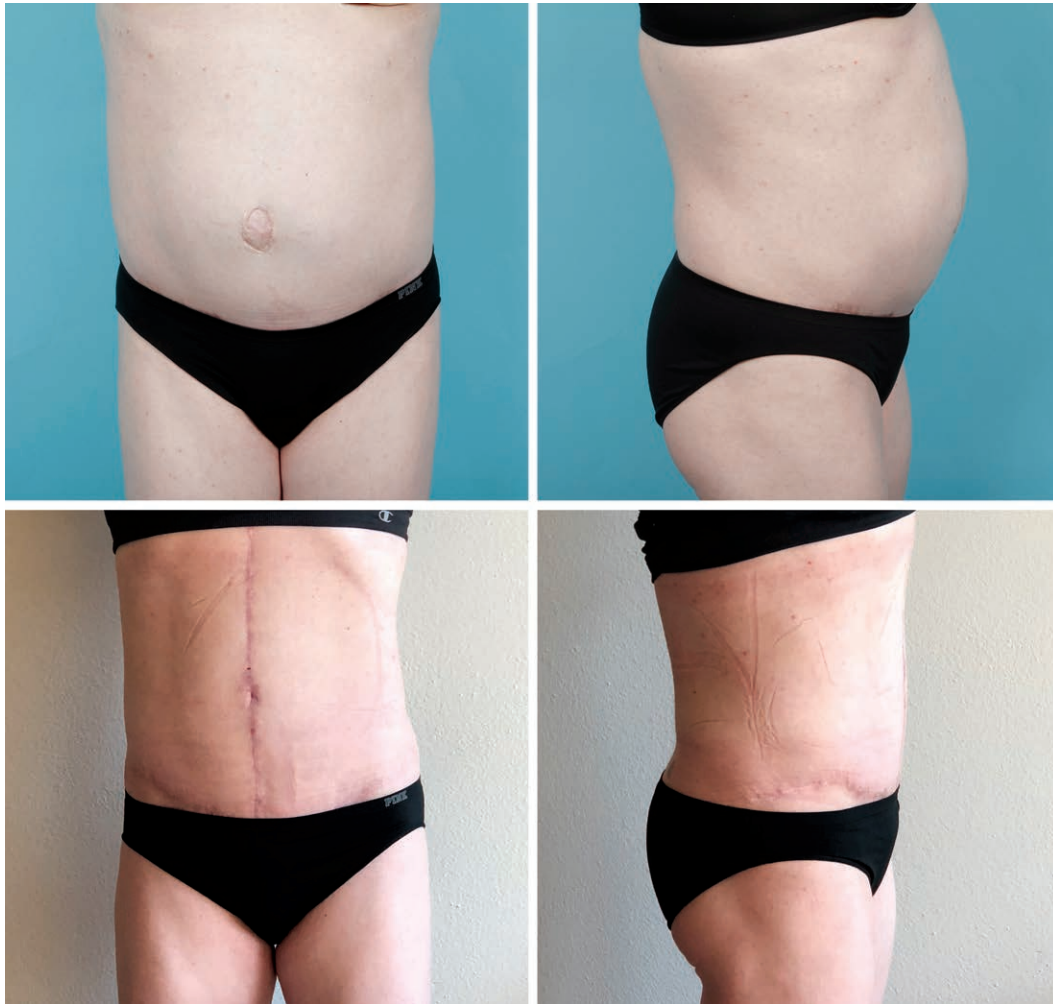
both in the midline, and just to the right and left of the midline. She presented to the clinic of the senior author (G.A.D.) 1 year after the second procedure, describing persistent distention and discomfort of her epigastrium (Fig. 4, *above*). On computed tomography, she had a 1-cm persistent rectus diastasis, and her rectus muscles were stretched, measuring approximately 10 cm from medial rectus to semilunar line on computed tomography (Fig. 5), and 12 cm intraoperatively. She underwent mesh abdominoplasty with resection of approximately 5 to 6 cm of the medial border of each rectus abdominis and placement of a 7.5-cm-wide well-fixed mesh in a retrorectus position. The patient recovered well and remains happy with her result at 7 months after surgery (Fig. 4, *below*).

## DISCUSSION

Rectus diastasis occurs not only because of mechanical stress placed on the abdominal wall

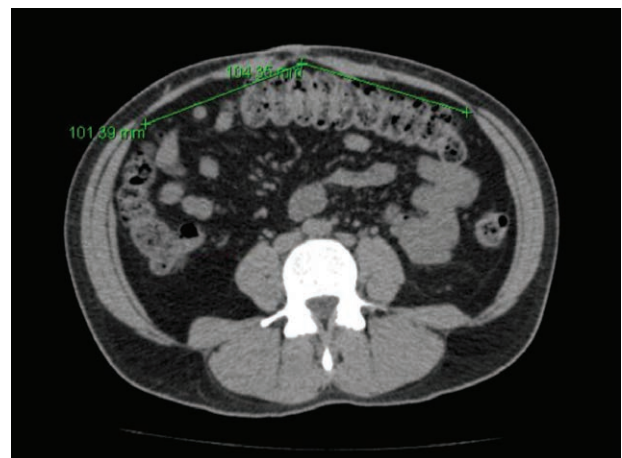

**Fig. 3.** Case 1. A 36-year-old woman (gravida 3, para 3) with minimal rectus diastasis on examination but significant abdominal bulging (*above*). She underwent mesh abdominoplasty as described in a prior report (Cheesborough JE, Dumanian GA. Simultaneous prosthetic mesh abdominal wall reconstruction with abdominoplasty for ventral hernia and severe rectus diastasis repairs. *Plast Reconstr Surg.* 2015;135:268–276), with resection of approximately 3.5 cm of medial rectus abdominis bilaterally and placement of wide, soft Prolene mesh in a retrorectus position. She remains happy at 18 months (*below*).



**Fig. 4.** Case 2. A 38-year-old woman who presented to the clinic after two prior abdominoplasty procedures performed by another surgeon. Before (*above*) and after (*below*) the patient underwent mesh abdominoplasty with resection of 6 cm of medial rectus muscle bilaterally.

by the growing fetus but also as a result of hormonal elastic changes of the connective tissues. Hormonal changes cause a decrease in the tensile strength of rectus fascia in pregnant women compared to that of nulliparous controls.<sup>5</sup> The interrectus distance starts to increase at approximately 14 weeks of gestation and continues to increase until delivery.<sup>6</sup> Some recovery of the linea alba occurs between delivery and 8 weeks' postpartum, after which time it plateaus and does not return to normal.<sup>7</sup> There are many published reports of mild improvement with exercise and physical therapy, although there is little high-quality evidence, and the degree of improvement of rectus diastasis width is unpredictable.<sup>8</sup> Reconstruction of the abdominal wall is important not only for aesthetics, but also for the restoration of core pressure. Improved core strength can lead to improved low back pain and trunk biomechanics.<sup>9-11</sup>



**Fig. 5.** Computed tomographic scan of case 2, a 38-year-old woman who presented to the clinic after two prior abdominoplasty procedures performed by another surgeon. One centimeter of rectus diastasis was present, and the rectus muscles were stretched to 10 cm wide.

Our data are generally consistent with the literature, although this study is the first to document the rectus muscle anatomical changes that occur with subsequent pregnancies. Serial ultrasound measurements in a single postpartum cohort over 1 year previously demonstrated thinner and wider muscles with stable cross-sectional area compared with nulliparous controls that did not recover with time.<sup>7</sup> The linea alba widens significantly after one pregnancy, but does not significantly increase with subsequent pregnancies in our measured patients. The rectus abdominis muscles widen significantly with initial pregnancy and further with a second pregnancy, but do not significantly widen further after additional gestations. The overall cross-sectional area of the muscle remains unchanged by pregnancy, but the shape of the muscle becomes thinner and wider, confirming that shape changes occur whereas total volume does not (Fig. 2). Although the average width of the rectus muscles after one pregnancy in this study was 6.61 cm, we have anecdotally seen several women present to the clinic with rectus muscles as wide as 10 cm on computed tomography.

The majority of surgeons perform repair of rectus diastasis as described by Pitanguy in 1967,<sup>12</sup> relying on sutures to hold the medial border of the rectus muscles in apposition. Although this repair is sufficient for women with minor postpartum changes of the abdominal wall, those with more significant rectus diastasis and rectus muscle changes should be approached with principles of hernia repair (Fig. 6). We know that hernias

repaired with sutures alone have a high propensity for failure. In a multicenter, randomized, controlled trial comparing suture versus mesh repair of incisional hernias, the 10-year recurrence rate for a suture compared to mesh repair was 63 percent and 32 percent, respectively.<sup>13</sup> We advocate that hernia patients and abdominoplasty patients with significant musculoaponeurotic laxity face similar abdominal wall biomechanics that lead to suture pull-through and failure of rectus diastasis repair. However, it has also been observed that there are cases of recurrent abdominal bulge despite intact repairs of the rectus diastasis.<sup>9,14</sup> We suspect that in these patients, another cause of persistent bulging is the postpartum change in the rectus abdominis muscles that remain uncorrected with a Pitanguy-type procedure that only addresses the linea alba. Increased rectus muscle width in turn increases the separation of the semilunar lines, worsening abdominal wall cosmetics. Some surgeons may attempt to correct this by increasing the extent of the standard rectus suture plication (Fig. 7). Although we report our success with medial muscular resection, how this compares to alternative techniques to address the muscle such as invagination of the muscle into the abdominal cavity is not established.

Recent experience at our institution has highlighted several postpartum patients who present after one or multiple abdominoplasty procedures with intact diastasis repairs, but who continue to report abdominal wall laxity and inability to strengthen their core despite regular muscle

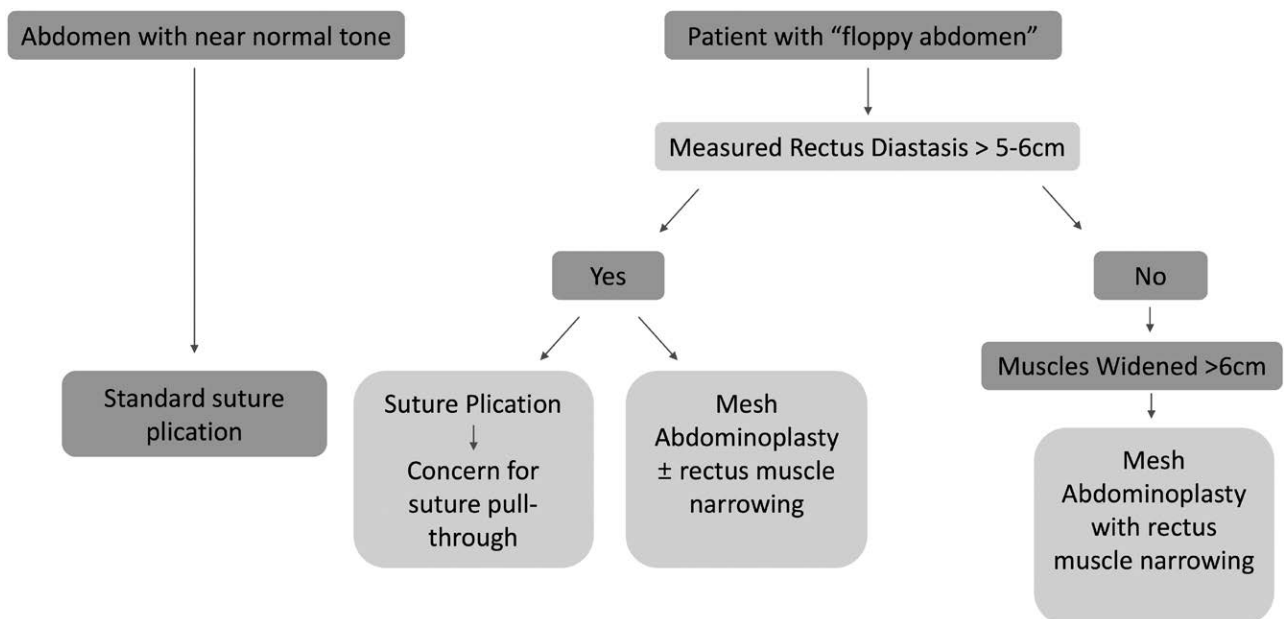
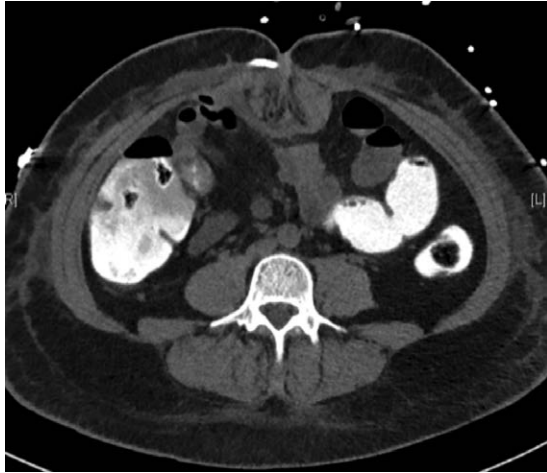

Fig. 6. Algorithmic approach to the abdominoplasty.





**Fig. 7.** Computed tomographic scan of a woman who underwent abdominoplasty performed by another surgeon, with severe invagination of rectus muscles.

training. These patients were adequately revised with narrowing of 3 to 4 cm of medial rectus muscles as described above and illustrated in Figure 8. Although narrowing has been performed with resection of the medial, thinner rectus muscle, altered techniques of bunching up the muscle are also possible once access to the retrorectus space is achieved.

One limitation of this study is that although we were able to measure changes in muscle shape after pregnancy, we do not know how this affects

sarcomere overlap and subsequent muscle tone. Future work to understand the biomechanics of postpartum changes in the abdominal wall musculoaponeurotic system and how this translates into muscle efficiency may be beneficial to determine the clinical significance of rectus muscle width, shape, and alignment.

## CONCLUSIONS

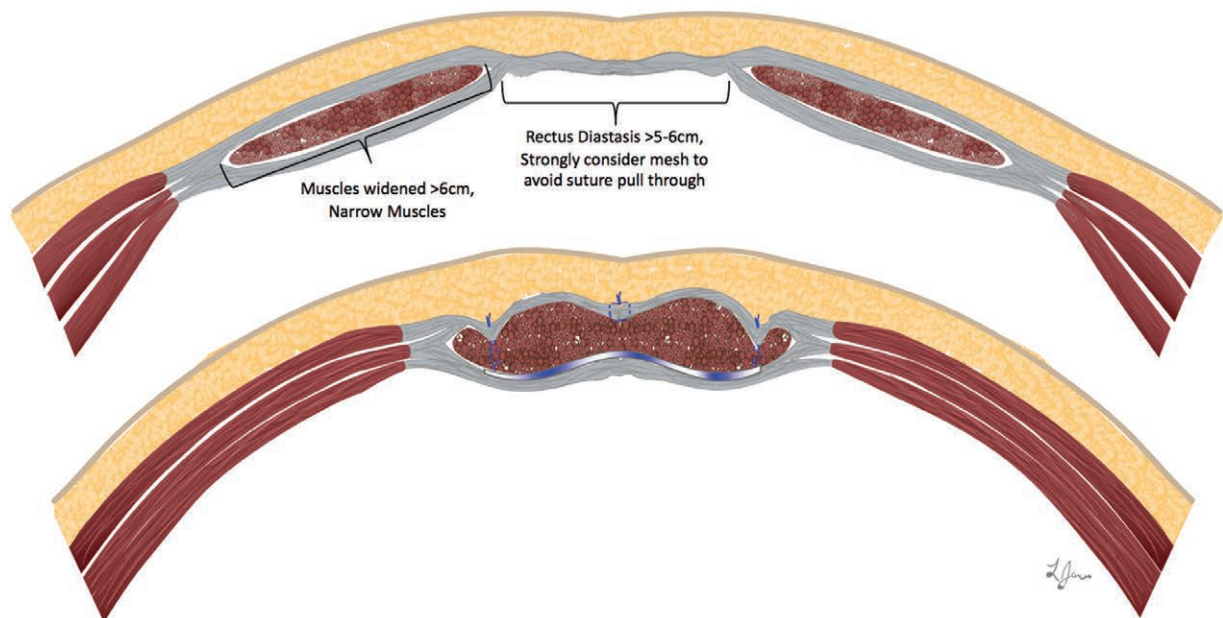
Understanding the abdominal wall changes caused by pregnancy is essential to successful abdominoplasty. We have found surgical restoration of abdominal tone depends not only on correction of the rectus diastasis but also on muscle width. Although this technique may be indicated for a minority of patients, evaluation of muscle width intraoperatively with rectus muscle narrowing may avoid patient dissatisfaction and revision procedures.

*Gregory A. Dumanian, M.D.*

Division of Plastic Surgery  
Northwestern Memorial Hospital  
675 North St. Clair Street, Suite 19-250  
Chicago, Ill. 60611  
gdumania@nm.org

## REFERENCES

1. American Society of Plastic Surgeons. 2017 plastic surgery statistics report. Available at: <https://www.plasticsurgery.org/documents/News/Statistics/2017/>



**Fig. 8.** Illustration depicting preoperative anatomy of the “floppy abdomen” (above) and postoperative anatomy (below). The muscles are narrowed and reapproximated with retrorectus mesh. Appropriate mesh tension is fixed with transrectus sutures, avoiding intercostal vessels in nerves during placement.

- plastic-surgery-statistics-full-report-2017.pdf. Accessed January 26, 2019.
2. Cormenzana PS, Samprón NM, Escudero-Nafs FJ. Secondary abdominoplasty. *Aesthetic Plast Surg.* 2008;32:503–508.
  3. Matarasso A, Schneider LF, Barr J. The incidence and management of secondary abdominoplasty and secondary abdominal contour surgery. *Plast Reconstr Surg.* 2014;133:40–50.
  4. Cheesborough JE, Dumanian GA. Simultaneous prosthetic mesh abdominal wall reconstruction with abdominoplasty for ventral hernia and severe rectus diastasis repairs. *Plast Reconstr Surg.* 2015;135:268–276.
  5. Landon CR, Crofts CE, Smith ARB, Trowbridge EA. Mechanical properties of fascia during pregnancy: A possible factor in the development of stress incontinence of urine. *Contemp Rev Obstet Gynecol.* 1990;2:40–46.
  6. Gilleard WL, Brown JM. Structure and function of the abdominal muscles in primigravid subjects during pregnancy and the immediate postbirth period. *Phys Ther.* 1996;76:750–762.
  7. Coldron Y, Stokes MJ, Newham DJ, Cook K. Postpartum characteristics of rectus abdominis on ultrasound imaging. *Man Ther.* 2008;13:112–121.
  8. Benjamin DR, van de Water AT, Peiris CL. Effects of exercise on diastasis of the rectus abdominis muscle in the antenatal and postnatal periods: A systematic review. *Physiotherapy* 2014;100:1–8.
  9. Oneal RM, Mulka JP, Shapiro P, Hing D, Cavaliere C. Wide abdominal rectus plication abdominoplasty for the treatment of chronic intractable low back pain. *Plast Reconstr Surg.* 2011;127:225–231.
  10. Doubkova L, Anđel R, Palascakova-Springrova I, Kolar P, Kriz J, Kobesova A. Diastasis of rectus abdominis muscles in low back pain patients. *J Back Musculoskelet Rehabil.* 2018;31:107–112.
  11. Toronto IR. The relief of low back pain with the WARP abdominoplasty: A preliminary report. *Plast Reconstr Surg.* 1990;85:545–555.
  12. Pitanguy V. Abdominal lipectomy: An approach to it through an analysis of 300 consecutive cases. *Plast Reconstr Surg.* 1967;40:384–391.
  13. Burger JW, Luijendijk RW, Hop WC, Halm JA, Verdaasdonk EG, Jeekel J. Long-term follow-up of a randomized controlled trial of suture versus mesh repair of incisional hernia. *Ann Surg.* 2004;240:578–583; discussion 583–585.
  14. Nahas FX, Ferreira LM, Mendes Jde A. An efficient way to correct recurrent rectus diastasis. *Aesthetic Plast Surg.* 2004;28:189–196.