Sonographic Evaluation of Common Peroneal Neuropathy in Patients With Foot Drop

Thomas H. Grant, DO, Imran M. Omar, MD, Gregory A. Dumanian, MD, Christy B. Pomeranz, MD, Vanessa A. Lewis, MD

The common peroneal nerve arises from the sciatic nerve and is subject to a variety of abnormalities. Although diagnosis is often is based on the clinical findings and electrodiagnostic tests, high-resolution sonography has an increasing role in determining the type and location of common peroneal nerve abnormalities and other peripheral nerve disorders. This article reviews the normal sonographic appearance of the common peroneal nerve and the findings in 21 patients with foot drop related to common peroneal neuropathy.

Key Words—common peroneal neuropathy; foot drop; high-resolution sonography

Common peroneal neuropathy is the most common mononeuropathy of the lower extremity.[1,2] Patients often present with a clinical syndrome known as "foot drop," which is characterized by weakness of the foot dorsiflexor muscles. Although the diagnosis is usually based on the patient's history and clinical findings, electromyography and magnetic resonance imaging (MRI) are commonly used to confirm the diagnosis.[3–5] Each of these modalities has drawbacks. Electromyography is useful for evaluating common peroneal nerve function but is limited in showing the type, site, and extent of a nerve abnormality. Magnetic resonance imaging provides excellent anatomic evaluation of the nerve but is an expensive test and can be uncomfortable for the patient due to long scanning times and claustrophobia. Additionally, MRI may be contraindicated in some patients. In recent years, high-resolution sonography has emerged as an excellent modality for examining peripheral nerves.[6–10]

Sonography offers several advantages in evaluation of peripheral nerve disorders, including the common peroneal nerve.[6,10] It is noninvasive and relatively inexpensive. High-frequency probes currently in use offer higher spatial resolution exceeding MRI scanners, allowing detailed morphologic evaluation of peripheral nerve abnormalities. On sonography, the entire length of the peripheral nerve can be imaged in a relatively short time, which is something difficult to do with MRI due to time constraints. Sonography also allows for dynamic imaging, which is useful for evaluation of entrapment and transient nerve impingement from such processes as myofascial herniation, orthopedic hardware, and scar tissue.[7]

Received September 6, 2013, from the Department of Radiology, Northwestern University, Chicago, Illinois USA (T.H.G., I.M.O., G.A.D., V.A.L.); and Department of Radiology, Weill Cornell Medical College, New York, New York USA (C.B.P.). Revision requested October 16, 2013. Revised manuscript accepted for publication July 8, 2014.

Address correspondence to Thomas H. Grant, DO, Department of Radiology, Northwestern University, 676 N Saint Clair, Suite 800, Chicago, IL 60611 USA.

E-mail: t-grant@northwestern.edu

Abbreviations
MRI, magnetic resonance imaging

doi:10.7863/ultra.34.4.705

Recent studies have demonstrated the ability of high-resolution sonography to accurately depict the common peroneal nerve width in cadavers and rabbits and have shown a statistically significant correlation between the electromyographic motor amplitude and peroneal nerve area, transverse breadth, and transverse length, as measured by sonography.[9,11] Sonography has demonstrated the ability to differentiate between nerve disorders such as nerve sheath tumors and extrinsic lesions compromising the nerve.[7] It also defines the exact level and extent of a lesion in cases of trauma.[11] In this article, we present the sonographic findings in a group of patients with foot drop related to common peroneal neuropathy.

Over a 3-year period, 21 patients (11 men and 10 women; age range, 19–70) with peroneal neuropathy causing foot drop were referred to our institution for evaluation of the common peroneal nerve. Patients were scanned in the prone position using a standardized technique with an iU22 ultrasound machine (Phillips Healthcare, Bothell, WA) equipped with a 12–5- or 17–5-MHz multifrequency transducer. Spatial compound sonography was used in all cases. The entire length of the common peroneal nerve was scanned from its bifurcation from the sciatic nerve to the fibular neck.

Gross and Sonographic Anatomy

The common peroneal nerve is a major terminal branch of the sciatic nerve. The nerve passes along the posterolateral aspect of the lateral head of the gastrocnemius muscle adjacent to the biceps femoris muscle, where it is located superficially. The nerve then crosses laterally to wind its way around the fibular neck as it passes through the peroneal tunnel, which is formed by the tendinous attachment of the superficial head of the peroneus longus muscle and lateral aspect of the proximal fibula (Figure 1). The nerve trifurcates at the fibular neck into a very small recurrent articular branch and larger superficial and deep peroneal nerves.

The basic sonographic anatomy of peripheral nerves has been well described in the literature.[7,10] The normal common peroneal nerve is of uniform thickness. The nerve is composed of hypoechoic nerve fascicles surrounded by echogenic connective tissue called perineurium (Figure 2). The external hyperechoic epineurium defines the outer layer of the nerve. The sonographic appearance of the entire common peroneal nerve is best depicted in the short axis. In this plane, the relationship of the nerve with adjacent known anatomic structures is readily depicted, since the nerve has a distinctive honeycomb pattern and can be readily followed. When scanned in the long axis, the nerve is more difficult to image because of its curvilinear course. However, once an abnormality is detected, the longitudinal scan best shows the relationship of the nerve with adjacent structures, the length of involvement, and the etiology.

Anatomic and Sonographic Findings of Common Peroneal Nerve Injury

Damaged nerves can be injured acutely or over a long period. After acute compression injuries, such as a stretching, a peripheral nerve will maintain a normal appearance. If the injury is prolonged, ischemic changes occur in the nerve fascicles.[7,10] A chronically damaged nerve becomes hypoechoic due to loss of the normal fascicles and damage to the epineurium (Figure 3). Usually no internal blood flow on color Doppler imaging can be detected in a peripheral nerve.[10] Detectable internal color flow is considered pathologic.

The common peroneal nerve is located superficially in the subcutaneous fat, lateral to the biceps femoris muscle. The common peroneal nerve is relatively "fixed" both at its origin from the sciatic nerve and also at the level of the fibular neck, making it particularly susceptible to compression. Sonography has been shown to accurately depict the relationship between the common peroneal nerve and the nearby osseous structures, aiding in the diagnosis

Figure 1. **A**, Relationship of the common peroneal nerve (red arrow) with the proximal fibula. After branching from the sciatic nerve, the common peroneal nerve extends caudally along the posterolateral aspect of the lateral head of gastrocnemius muscle and then winds around the fibular neck to the lateral compartment musculature. The nerve has a superficial location, making it susceptible to trauma. **B**, The common peroneal nerve passes through the fibular tunnel (blue arrow), a canal formed by the tendinous attachment of the superficial head of the peroneus longus muscle and lateral aspect of the proximal fibula. The nerve is relatively tethered in this area and is prone to entrapment.

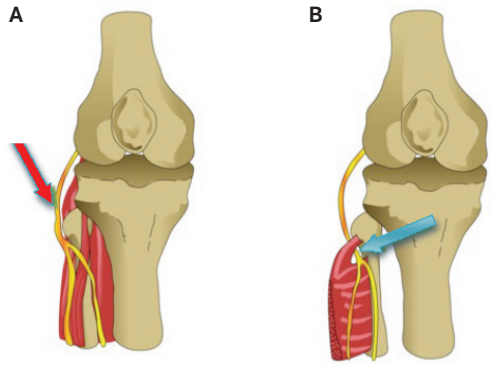

of entrapment.[12,13] Common peroneal neuropathy can occur in the setting of repetitive trauma (runners and cyclists), habitual prolonged leg crossing, systemic diseases (diabetes and amyloidosis), fracture of the proximal fibula, rapid weight loss after bariatric surgery, anatomic variants, peripheral nerve sheath tumors, and ganglion cysts arising from the proximal tibiofibular joint.[1,2,6,10,12–16] In the pathologic state, the common peroneal nerve becomes flattened at the site of compression and swollen proximally, with loss of the normal fascicular architecture[7,10] (Figure 3). Recent studies have shown that the common peroneal nerve will have a larger mean area when measured at or above the fibular head by high-resolution sonography in patients with common peroneal neuropathy.[17]

Figure 2. Sonographic appearance of the normal common peroneal nerve (calipers). The normal nerve is of uniform thickness and shows internal striations due to the interface between the perineurium and the individual fascicles that comprise the nerve (arrows). The echogenicity of the normal nerve is lower than that of normal tendon and greater than that of normal skeletal muscle.

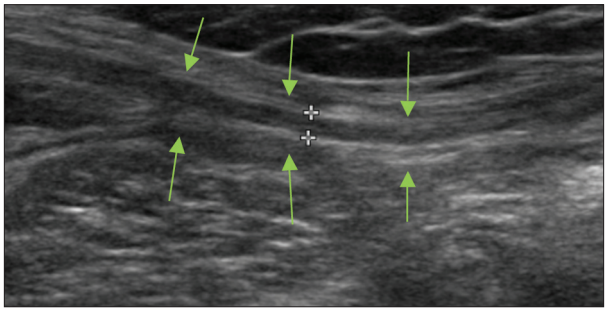

Figure 3. Image from a 23-year-old woman with foot drop and common peroneal nerve entrapment at the level of the fibular tunnel. The common peroneal nerve is enlarged at the level of the fibular tunnel, with loss of the normal striated internal echo texture (calipers and thick arrows). The hyperechoic cortex of the fibular neck can be seen at the bottom of the image (thin arrows).

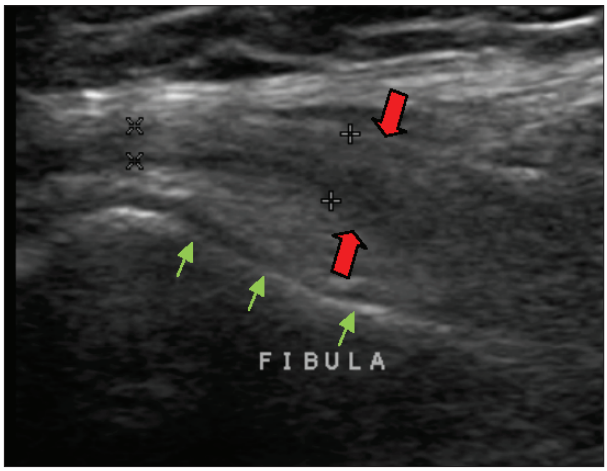

Traumatic Neuropathy

Traumatic knee dislocation and postsurgical changes in the fibular region represent important causes of entrapment.[12] Common peroneal nerve palsy has been reported after knee ligament reconstruction.[13] Postsurgical scar tissue can compress the common peroneal nerve, causing symptoms of foot drop (Figure 4). An unreported cause of common peroneal neuropathy was a fascial defect adjacent to the biceps femoris muscle, causing common peroneal nerve compression (Figure 5). Iatrogenic causes are very rare. However, we encountered a 62-year-old woman with common peroneal neuropathy from an inadvertent non–image-guided injection of hyaluronan into the biceps

Figure 4. Images from a 39-year-old man presenting with foot drop and a history of open reduction internal fixation surgery. Sonography shows scar tissue (arrows) compressing the common peroneal nerve (calipers) on sagittal (**A**) and transverse (**B**) views.

A

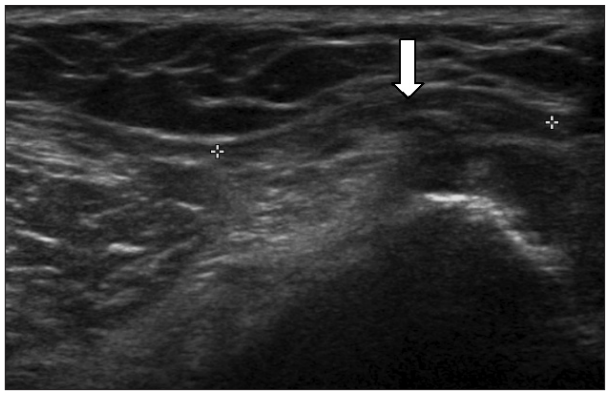

B

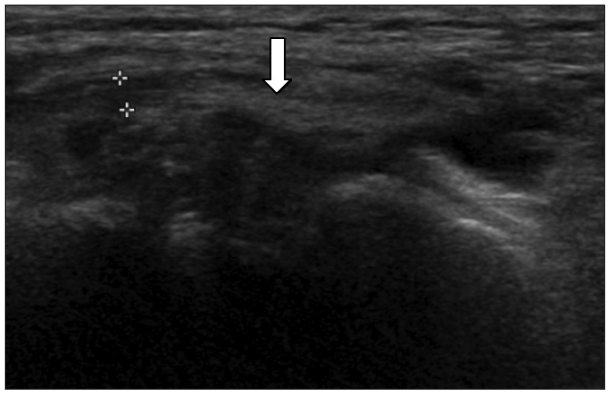

femoris muscle performed for treatment of painful knee osteoarthritis (Figure 6). The patient recovered after 4 months of conservative management.

Entrapment Neuropathy

Although the common peroneal nerve may be entrapped at any location along its course, it is most common at the fibular neck because of its superficial location and fixed position. In this location, the common peroneal nerve is vulnerable to repetitive trauma. The nerve is focally compressed by thickened fascia and fibrosis, which surround it. Entrapment syndromes involving the biceps femoris have also been reported. Hypertrophy or abnormal insertion of the biceps femoris tendon can create a muscular tunnel between the short head of the biceps femoris and the lateral gastocnemius muscle. The entrapped nerve can eventually lead to edema and fatty atrophy of the anterior and lateral compartment calf muscles[7] (Figure 7).

Other Causes of Common Peroneal Neuropathy

Common peroneal nerve compression may also result from space-occupying lesions such a ganglion cysts, soft tissue tumors, and bone tumors. Ganglion cysts arising from the proximal tibiofibular joint are benign and often multiseptated masses surrounded by a dense fibrous connective tissue capsule.[16] They can cause a mass effect on the common peroneal nerve and resultant foot drop (Figure 8). If possible, the neck of the cyst should be documented to aid in surgical planning. Intraneural ganglion cysts can also occur but are much less common (Figure 8).

Figure 5. Image from a 44-year-old patient with a recent history of knee surgery and new-onset foot drop. Sonography shows a defect in the biceps femoris muscle (arrows), which causes intermittent compression on the common peroneal nerve (arrowhead). A surgical procedure was required to relieve the symptoms.

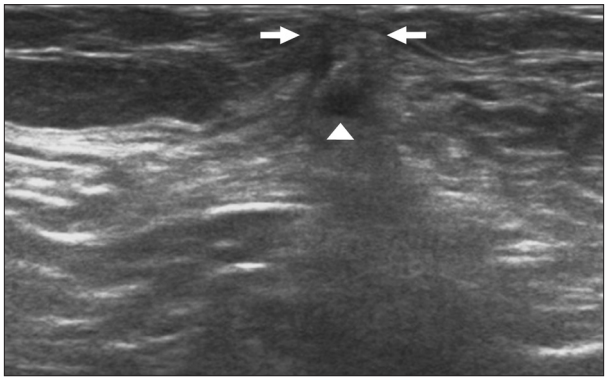

Figure 6. Image from a 62-year-old woman with common peroneal neuropathy after hyaluronan injection into the biceps femoris muscle (BF). Sonography shows enlargement of the common peroneal nerve with loss of the fascicular pattern (arrowheads). FIB indicates fibula.

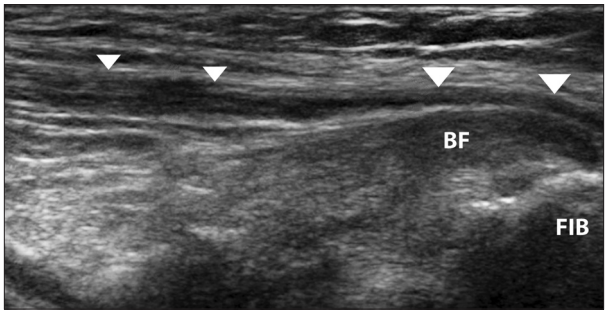

Figure 7. Images from a 69-year-old woman with right foot drop. **A**, Sonography shows a focally thickened and hypoechoic common peroneal nerve (calipers and arrows). **B**, Subsequent MRI shows edema of the tibialis anterior muscle (thick arrow) with common peroneal nerve enlargement (thin arrow).

A

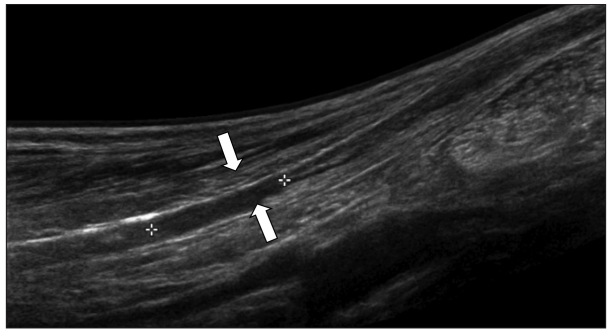

B

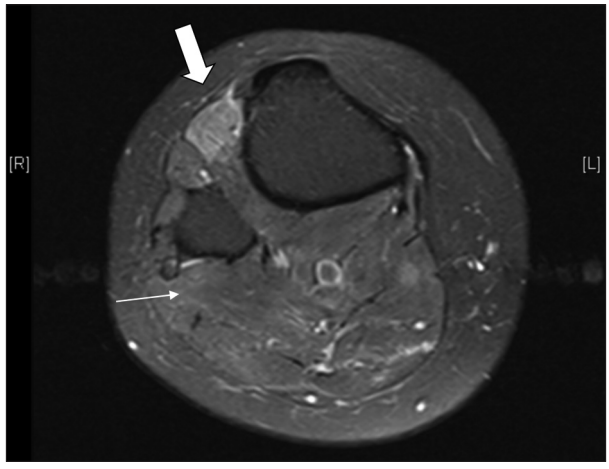

The most widely accepted theory is related to synovial proliferation extending into the nerve sheath from the proximal tibiofibular joint.[18,19]

Lipomas (Figure 9) are benign masses composed of mature fat cells surrounded by a thin, fibrous capsule. Lipomas can occur anywhere in the body where fat cells are present, most notably subcutaneous fat and muscle. There are case reports of peroneal nerve palsy due to compression by subcutaneous lipomas.[20] On sonography, an elongated, circumscribed, often encapsulated mass in the subcutaneous fat that is isoechoic compared to the adjacent normal subcutaneous fat should indicate the diagnosis of lipoma.

Peripheral nerve sheath tumors can involve the common peroneal nerve. Schwannomas and neurofibromas are the most common and cannot be distinguished on sonography.[21] Neurofibromas can be localized, diffuse, or plexiform and associated with neurofibromatosis.[21] Most peripheral nerve sheath tumors are homogeneous and hypoechoic and may show increased posterior acoustic enhancement.[21] Increased flow on color Doppler imaging has also been reported (Figures 10 and 11).

Conclusions

Sonography is a highly effective tool for evaluation of common peroneal neuropathy in patients with foot drop. Sonography not only evaluates the nerve but also locates the type and extent of the neuropathy. It is a relatively inexpensive study, is comfortable for the patient, and allows for dynamic imaging. Advances in ultrasound technology allow for ever-increasing use in the detection of nerve disorders.

Figure 8. Images from a 55-year-old woman with left foot drop in the setting of an intraneural ganglion cyst. Transverse (**A**) and sagittal (**B**) sonograms show a circumscribed anechoic mass (arrow) arising from the proximal tibiofibular joint. The lesion causes a mass effect on the adjacent common peroneal nerve, resulting in nerve enlargement and loss of the normal internal striated echo texture (calipers).

A

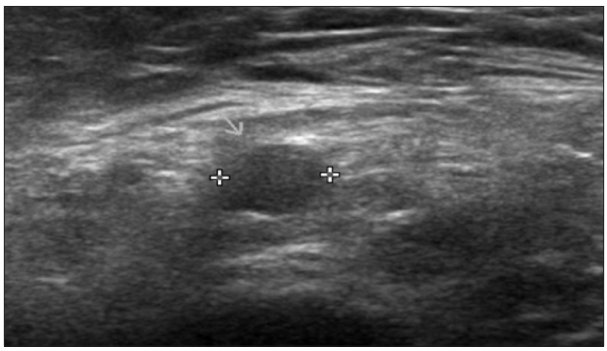

B

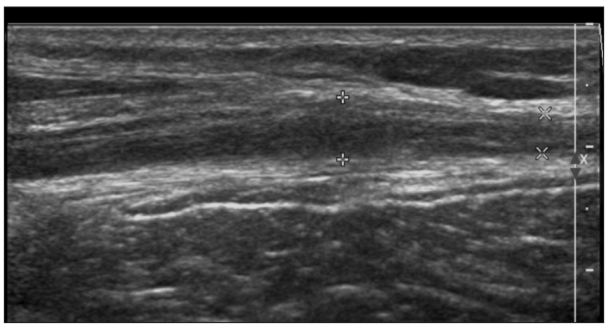

Figure 9. Images from a 38-year-old woman with left foot drop secondary to a lipoma. Transverse (**A**) and sagittal (**B**) sonograms show a circumscribed, ovoid, subcutaneous mass that is isoechoic to the adjacent subcutaneous fat (calipers). The lesion causes a mass effect on the adjacent common peroneal nerve (PER NV), with enlargement of the nerve proximal to the lesion.

A

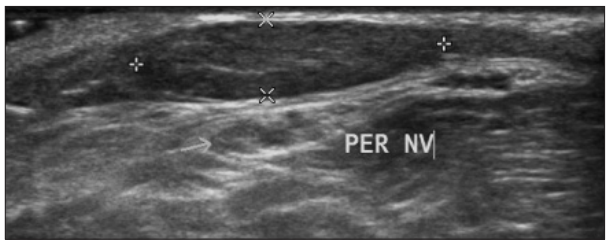

B

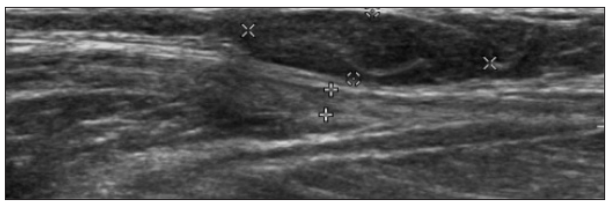

Figure 10. Images from a 55-year-old man with type 1 neurofibromatosis and foot drop. **A**–**D**, Sonography shows two hypoechoic masses within the common peroneal nerve, consistent with neurofibromas (arrows). In each lesion, the common peroneal nerve can be seen entering and exiting the lesion (arrowheads). Color Doppler imaging (**B**) shows flow within one of the lesions. **E**–**G**, Subsequently performed MRI of the knee with contrast shows two enhancing nodules (arrows) in the common peroneal nerve, corresponding to the lesions documented on sonography.

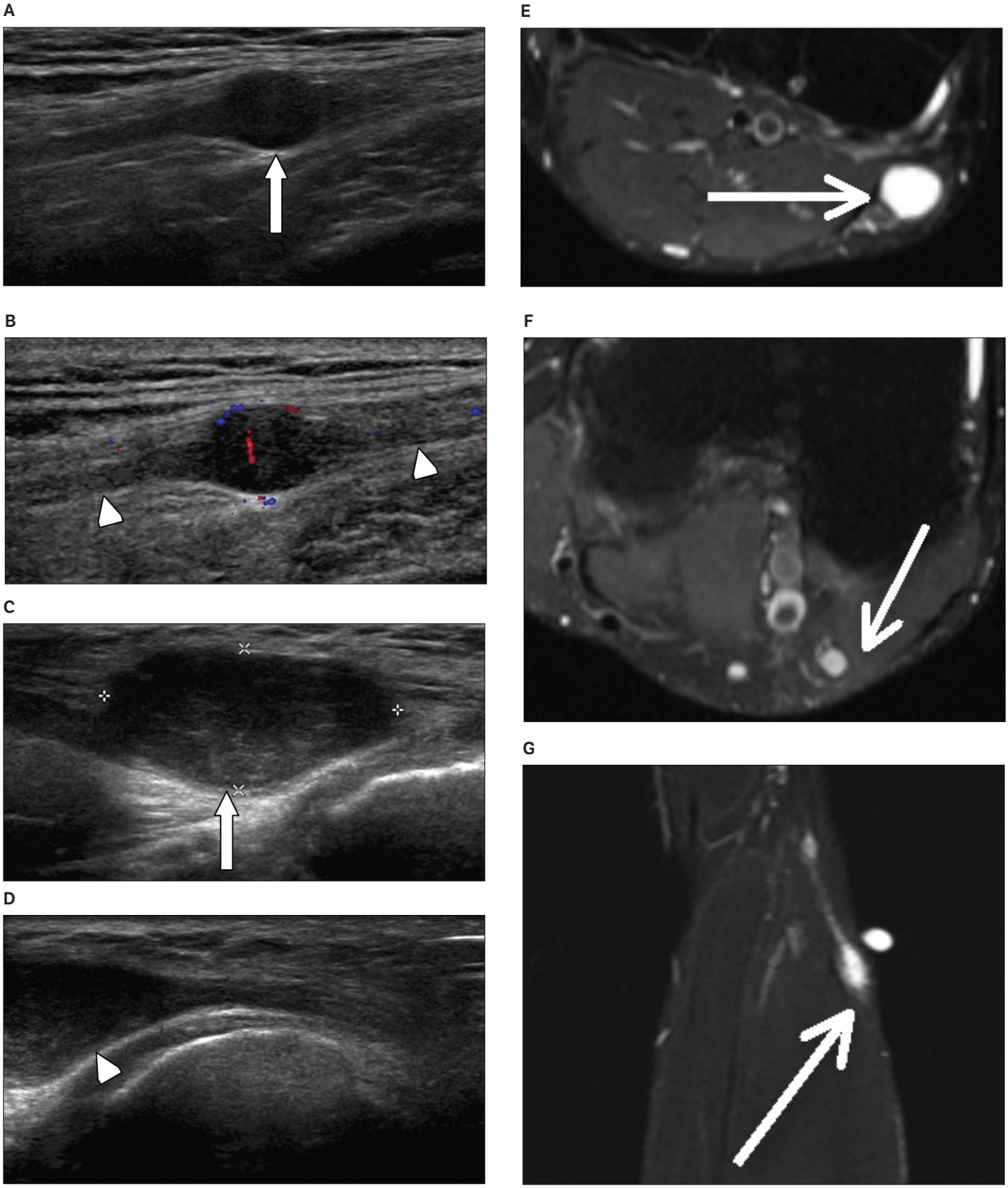

Figure 11. Images from a 45-year-old man with right foot drop due to a schwannoma. Transverse (**A**) and longitudinal (**B**) sonograms show a hypoechoic, encapsulated mass (calipers in **A**) in close association with the common peroneal nerve (calipers in **B**).

A

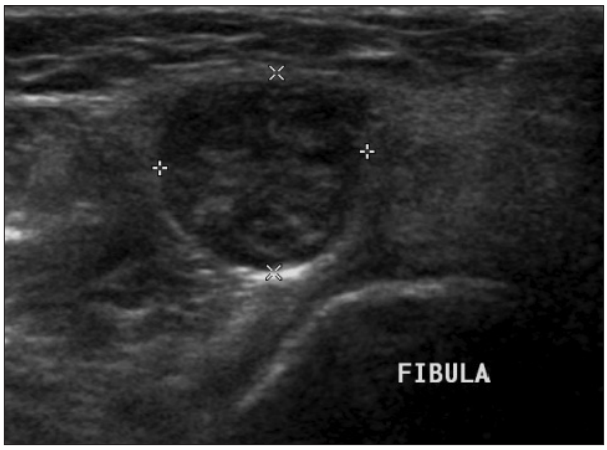

B

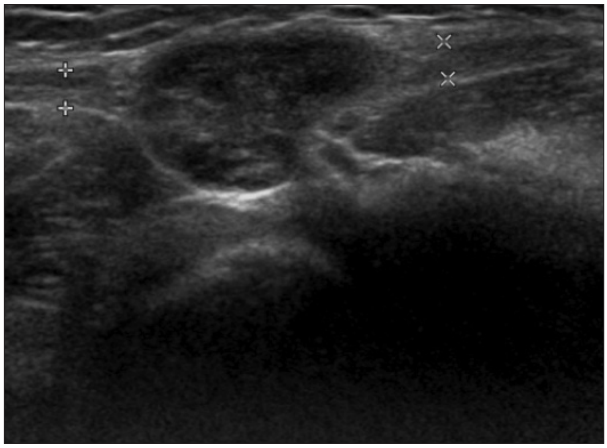

References

1. Campbell WW. Diagnosis and management of common peroneal compression and entrapment neuropathies. *Neurol Clin* 2003; 15:549–567.
2. Stewart JD. Foot drop: where, why, and what to do? *Pract Neurol* 2008; 8:158–169.
3. Young NP, Sorenson EJ, Spinner RJ, Daube JR. Clinical and electrodiagnostic correlates of peroneal intraneural ganglia. *Neurology* 2009; 72:447–452.
4. Donovan A, Rosenberg ZS, Cavalcanti CF. MRI imaging of entrapment neuropathies of the lower extremity, part 2: the knee, leg, ankle, and foot. *Radiographics* 2010; 30:1001–1019.
5. Kim JY, Ihn YN, Kim JS, Chun KA, Sung MS, Cho KH. Non-traumatic peroneal nerve palsies: MRI findings. *Clin Radiol* 2007; 62:58–64.
6. Peer S, Kovacs P, Harpf C, Bodner G. High-resolution sonography of lower extremity peripheral nerves: anatomic correlation and spectrum of disease. *J Ultrasound Med* 2002; 21:315–322.
7. Martinoli C, Bianchi S, Gandolfo N, Valle M, Simonetti S, Derchi LE. US of nerve entrapments in osteofibrous tunnels of the upper and lower limbs. *Radiographics* 2000; 20(suppl 1):S199–S217.
8. Beekman R, Visser LH. High-resolution sonography of the peripheral nervous system: a review of the literature. *Eur J Neurol* 2004; 11:305–314.
9. Lo YL, Fook-Chong S, Leoh TH, et al. High resolution ultrasound as a diagnostic adjunct in common peroneal neuropathy. *Arch Neurol* 2007; 64:1798–1800.
10. Bianchi S. Ultrasound of the peripheral nerves. *Joint Bone Spine* 2008; 75:643–649.
11. de Kool BS, van Neck JW, Blok JH, Walbeehm ET, Hekking I, Visser GH. Ultrasound imaging of the rabbit peroneal nerve. *J Peripher Nerv Syst* 2005; 10:369–374.
12. Gruber H, Peer S, Meirer R, Bodner G. Peroneal nerve palsy associated with knee luxation: evaluation by sonography—initial experience. *AJR Am J Roentgenol* 2005; 185:1119–1125.
13. Montgomery AS, Birch R, Malone A. Entrapment of a displaced common peroneal nerve following knee ligament reconstruction. *J Bone Joint Surg Br* 2005; 87:861–862.
14. Meylaerts L, Cardinaels E, Vandevenne J, et al. Peroneal neuropathy after weight loss: a high-resolution ultrasonographic characterization of the common peroneal nerve. *Skeletal Radiol* 2011; 40:1557–1562.
15. Viera RL, Rosenberg ZS, Kiprovski K. MRI of the distal biceps femoral muscle: normal anatomy, variants, and association with common peroneal nerve entrapment neuropathy. *AJR Am J Roentgenol* 2007; 189:549–555.
16. Damron TA, Rock MG. Unusual manifestations of proximal tibiofibular joint synovial cysts. *Orthopedics* 1997; 20:250–230.
17. Visser LH, Hens V, Soethout M, De Deugd-Maria V, Pijnenburg J, Brekelmans GJ. Diagnostic value of high-resolution sonography in common fibular neuropathy at the fibular head. *Muscle Nerve* 2013; 48:171–178.
18. Visser LH. High-resolution sonography of the common peroneal nerve: detection of intraneural ganglia. *Neurology* 2006; 67:1473–1475.
19. Spinner RJ, Hebert-Blouin MN, Rock MG, Amrami KK. Extreme intraneural ganglion cysts. *J Neurosurg* 2011; 114:217–224.
20. Hsu YC, Shih YY, Gao HW, Huang GS. Subcutaneous lipoma compressing the common peroneal nerve and causing palsy: sonographic diagnosis. *J Clin Ultrasound* 2010; 38:97–99.
21. Reynolds DL, Jocaobson JA, Inampudi P, Jamadar DA, Ebrahim FS, Hayes CW. Sonographic characteristics of peripheral nerve sheath tumors. *AJR Am J Roentgenol* 2004; 182:741–744.