

# CHAPTER 69 ■ ABDOMINAL WALL RECONSTRUCTION

GREGORY A. DUMANIAN

Why should plastic surgeons perform abdominal wall reconstruction? If the abdomen is thought of as viscera with overlying muscle and skin, who better to deal with issues of soft-tissue cover of the abdominal compartment than plastic surgeons? This chapter provides the reader a framework for the management of all types of abdominal wall situations, including wounds, fistulae, and hernias. Management of the abdominal wall depends on the following:

1. An understanding of the forces on the abdominal wall that lead to hernia formation.
2. Prompt closure of open wounds and the conversion of enteric fistulae into ostomies.
3. Delaying definitive reconstruction until patients are well-nourished and have closed wounds.
4. A realization that abdominal wall reconstruction involves two intertwined decision trees regarding repair of the abdominal wall and treatment of the skin. Maintenance of skin blood supply rather than wide undermining of skin flaps reduces complications.

---

## FORCES ON THE ABDOMINAL WALL

---

The abdomen is a cylinder with a uniform internal pressure. The posterior third of the cylinder is rigid. With inspiration, the Valsalva maneuver, or body movement, the diaphragms descend and the abdominal wall muscles contract to increase intra-abdominal pressure. This contraction is isometric, thereby increasing muscle fiber tension without shortening. The increased internal abdominal pressure is matched by the increased tone of the abdominal wall muscles. When there is a local imbalance of intra-abdominal pressure and muscle tone, a bulge becomes apparent. Examples of bulges include the lower abdominal area in women after childbirth, and the lateral bulges (with associated muscle denervation) often seen after flank incisions. What is important is the uniformity of the abdominal wall counterpressure. When this uniformity is lost, bulges and hernias emerge. Episodic high peaks of intra-abdominal pressure caused by chronic coughing and episodic lifting of heavy objects further impact areas of the abdominal wall with decreased counterpressure. Obesity plays a role in two ways—first, there is an increased amount of tissue inside the abdominal wall raising baseline intra-abdominal pressure. Second, the abdominal wall must support a greater amount of weight above the diaphragm, increasing both the intensity and number of peaks of high intra-abdominal pressure.

When intra-abdominal pressure is consistently greater than the active and static counterpressure of the abdominal wall,

areas of weakness will protrude outward, forming hernias and bulges. The outer covering of hernia sacs is scar, whereas bulges are comprised of some aspects of intact (although weakened, partially resected, or denervated) abdominal wall. Hernias demonstrate “necks” where the abdominal wall is intact, whereas bulges are smoother without abrupt changes. Hernias typically expand with time, because of the tendency of scar to stretch and deform, and therefore do not tend to reach a steady state. Bulges, on the other hand, can reach a steady state in size when the inelasticity of the tissue is matched to the abdominal wall pressure.

As abdominal viscera move into the growing hernia sac, derangements of normal patterns of intra-abdominal pressure occur. As stated earlier, with less viscera in the abdomen, the intra-abdominal pressure decreases. The Valsalva maneuver, used so intuitively to brace the body during exertion, becomes ineffective. The abdominal wall muscles now contract isotonic rather than isometrically. With contractions of the abdominal musculature, the muscles shorten, the hernia increases in size, but intra-abdominal pressure does not increase. Abdominal wall work increases, because isotonic contraction consumes more energy than does isometric contraction.

The goal of a hernia repair is to return uniformity to abdominal wall counterpressure against the viscera, improving the counterpressure where it is weak, and possibly weakening the abdominal wall where it is strong. Mesh repairs and the “separation of parts” hernia repair restore counterpressure in different ways (Fig. 69.1) (1). In mesh repairs, a cap or lid is sutured to replace the weak area of the abdominal wall. The strength of the mesh to resist outward deformation is achieved through the strength of the circumferential attachment of the mesh to the normally innervated abdominal wall. The larger the hernia, the further the unsupported center of the mesh will be from innervated abdominal wall, and the greater will be the bowing. In contradistinction, the separation of parts hernia repair releases the external oblique muscle and fascia from its attachment to the midline rectus abdominis muscles. A direct reapproximation of the rectus muscles in the midline strengthens the counterpressure at the hernia site, while simultaneously weakening the sides.

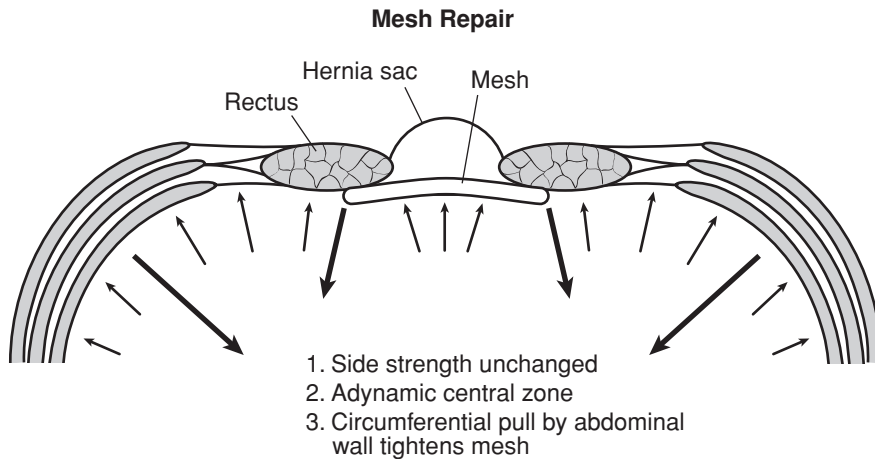
After repair of massive hernia defects, despite the magnitude of the procedure, patients often claim they feel stronger than they did before surgery. I attribute this sense of well being to a restored ability to raise intra-abdominal pressure, and for a reversion to isometric contraction of the abdominal wall muscles.

---

## CLOSING THE WOUND

---

After dehiscence of a laparotomy incision, the operative field is inflamed, and the patient is often nutritionally depleted. A



**FIGURE 69.1.** Diagram of forces on the abdominal wall after a laparoscopic mesh repair. (Redrawn from Dumanian GA, Denham W. Comparison of repair techniques for major incisional hernias. *Am J Surg.* 2003;185:61, with permission.)

good strategy after such a surgical complication, is that the next procedure “had better work.” Early wound closure in the simplest manner possible has multiple benefits, including patient comfort, ease of wound care, and a decreased incidence of enterocutaneous fistulae (2). When devising a plan to close the wound, the following questions must be answered:

1. Are the viscera “frozen,” and what are the chances for an evisceration?
2. Do bowel contents need to be controlled?
3. What are the location, size, and characteristics of the wound? Should the wound be modified to help achieve wound closure?

### Evisceration

Little is written about evisceration. Patient management depends on why the abdominal wall lost integrity. Rarely, a purely technical problem of wound closure leads to a disruption of the suture line. Patients at exploration who have pristine wounds with minimal capillary leak, and can simply be re-closed. More commonly, the patient has an ileus, several days have elapsed since surgery, and the evisceration is proceeded by intra-abdominal fluid leaking through the skin suture line. These are contaminated wounds, and prone to further difficulties. Therefore, a minimalist approach to prevent a second evisceration and to control the infected soft tissues should be employed. As alluded to earlier, abdominal wall reconstructive surgery can be broken into two parts—the management of the abdominal wall and the management of the skin. For the abdominal wall, an absorbable polyglycolic acid mesh is placed using a running absorbable monofilament suture to prevent a second evisceration and to keep the viscera in their proper domain. For the skin, we have temporized the situation with a vacuum device, or in relatively clean situations, closed the skin over drains. Eventual skin closure is performed by delayed primary closure, skin grafts, or by secondary intention. When the skin gapes widely and several months are expected before closure by secondary intention, skin grafting provides the simplest and most reliable closure as is discussed below.

Why not try to reclose the abdomen directly or with the aid of bioprosthetic mesh? In an infected field with swollen underlying bowel, the chance for failure is high. It is better to leave the abdominal muscles where they are and to patch the central defect. Mass closures with retention sutures can occasionally be successful, but hernias usually develop, and the sutures cause necrosis of the skin and medial aspects of the rectus muscles.

### Open Wounds after Abdominal Surgery

Dehiscence of the abdominal closure is not uncommon after gastrointestinal surgery. Clues for fascial dehiscence include loose abdominal sutures at the base of the wound, a history of a “seroma” drained from underneath the skin (intra-abdominal fluid emerging through the open abdominal wall), and a computed tomography (CT) scan demonstrating bowel loops located anterior to the abdominal fascia. Informed consent at this juncture is important. Patients with open abdominal wounds after a laparotomy have a fairly high incidence of developing hernia formation. Patients with a fascial dehiscence essentially have a hernia already, although it is not yet manifest. If and when the patient develops a hernia, it is not because of improper treatment of the open abdominal wound; rather, it is expected. Another point for informed consent is that patients with fascial dehiscence are at risk for bowel injury during debridement. However, waiting and using dressings to treat the wound *also* risks bowel injury, because the intense local inflammation may cause an opening at a bowel suture line or site of a previous serosal tear. **I believe that early wound closure increases patient comfort, reduces the chances for bowel injury, and is the first step in abdominal wall reconstruction.** The most reliable method of wound closure is with skin grafts. The “two-dimensional” healing of skin grafts is not dependent on the patient’s nutrition, unlike the “three-dimensional” healing required of sutured skin flaps. The timing from the most recent laparotomy is critical. Wounds that are grafted 10 to 14 days after the last laparotomy in patients with demonstrated normal wound healing have a low risk for evisceration at the time of skin grafting. A week is added for patients on steroids. The visual clue that the open abdomen is ready for skin grafting is that individual bowel loops are no longer discernible amidst the sea of granulation tissue.

At the time of surgery, the overhanging skin edges are saucerized to present a flat surface for grafting. Skin bridges are divided. Blunt dissection with a large periosteal elevator is used to debride the granulation tissue down to a clean base. So long as only the bowel surface and not individual bowel loops are debrided prior to skin grafting, the loops stay matted to the undersurface of the abdominal wall and to each other. The grafts are stapled to the edges of the base of the defect, and a moist dressing applied. Moist dressing changes on the graft itself are initiated 2 to 3 days after the placement of the graft. Unlike the base of the wound, the sidewalls take skin graft poorly, probably as a result of poor vascularity and significant motion on the sides of the skin flaps.

---

## Fistulae

---

Every tube placed percutaneously into the bowel is a fistula. The difference between controlled fistulae seen on a general surgery service and the fistulae in the midst of an open abdominal wound is lack of overlying soft tissue. When a percutaneous tube is removed, the overlying integument contracts around the tract. When a fistula occurs in the center of a wound, there is no overlying soft tissue to help the fistula to seal. Bowel rest and octreotide help decrease the flow of succus entericus across the fistula and aid in wound management. The granulation tissue surrounding the fistula prevents adherence of an ostomy device to catch the fluid. The only manner to stop the fistula is to perform a bowel resection and repair, but the patient is usually in no condition for an intra-abdominal procedure. The plan, therefore, is to convert the fistula into an ostomy, allowing for patient comfort and cleanliness, and to delay definitive surgery. Skin grafts stick well to the surrounding tissue, and the key maneuver in the operating room is to temporarily keep the surgical site dry for the first 24 to 48 hours after graft placement. Typically, suction is applied to a rubber drain placed into the fistula to remove succus. Attention to detail is critical to keep this tube functioning early after surgery. After 48 hours, moist dressings are begun to the entire grafted area for cleanliness and to aid epithelialization. After 14 to 21 days, the skin graft is strong enough to withstand placement of an ostomy bag. Three to 6 months must pass for inflammation to subside and the wound to soften before definitive reconstruction (3).

---

## Wound Shape and Position

---

In the infraumbilical area in the obese patient, some wounds are so deep and with so much fat necrosis that local wound care does not suffice to achieve closure. In these selected patients, a panniculectomy encompassing the necrotic tissue is helpful to change the shape of the wound. Even if part of the wound is left open on dressings, a transversely oriented wound closes much more quickly than a vertically oriented wound. Prior to panniculectomy, a CT scan is obtained to confirm the position of the bowel to avoid an iatrogenic enterocutaneous fistula.

---

## ABDOMINAL WALL AND SOFT-TISSUE RECONSTRUCTION (VENTRAL HERNIA REPAIR)

---

As mentioned above, successful hernia repair requires a plan for the abdominal wall and for achieving stable skin coverage. The timing for abdominal wall reconstruction is also important. In the ideal case, the patient has a stable, closed wound with soft, pliable tissues over the hernia sac. **An easy rule to remember is that if the hernia is expanding, it is ready to be fixed.** An expanding hernia implies that bowel adhesions and scar attaching the bowel to the abdominal wall has significantly softened and will be straightforward to dissect.

---

### Stable Soft Tissues: Midline Abdominal Wall Defects

---

When the skin and subcutaneous tissues are pliable, no wounds are present, and no gastrointestinal surgery is planned, many options exist for this hernia repair. For small hernias less than 3 cm across, a direct repair is often performed, although there is still a surprisingly high recurrence rate (4). For hernias larger than 3 cm, a laparoscopic mesh hernia repair is ideal. These la-

paroscopic repairs are shown in the literature to have a recurrence rate in the 3% to 4% range, low incidences of infections, short hospitalizations, and quick recoveries (5). The hernias should not have a neck >10 cm to allow for 3 cm of overlap between the mesh and the posterior aspect of the abdominal wall, while still having room to place and maneuver the trocars. Other options for treatment of hernias with stable soft tissues include open mesh repairs and closure with sliding myofascial rectus abdominis flaps (modified separation of parts procedure, as is discussed below).

Conceptually, mesh repairs are lids attached to the top of an open pot. The quality of the attachment is paramount—when mesh repairs fail, it is typically because of a lack of a durable attachment of the mesh to the abdominal wall. Mesh can be laced on top of the abdominal wall, sewn directly to the edges of the defect, or used as an underlay. The first two methods minimize the amount of bowel in contact with the mesh. Mesh underlays serve to maximize the attachment of the mesh to the abdominal wall, using the pressure of the viscera to push the mesh against the abdominal wall. For mesh underlays, sutures are used to create at least 3 cm of overlap between abdominal wall and the mesh. Enough sutures are needed to prevent the herniation of a bowel loop between stitches, but too many sutures can cause ischemic necrosis of the edge of the abdominal wall, and in turn lead to a poor mesh attachment.

Numerous nonabsorbable mesh alternatives exist. Selection of one versus another depends largely on the complication profile associated with each of the meshes. A brief description of the mesh choices currently available and the associated complications for each follows.

### Expanded Polytetrafluoroethylene Mesh

Several formulations of this mesh exist (Gore-Tex, W.L. Gore and Assoc., Flagstaff, AZ). The advantage of this material is the smooth, nonporous surface of the mesh to prevent bowel adhesions. The lack of adhesions to the mesh is both its most favorable characteristic and its major drawback. Placed intraperitoneally during laparoscopic repairs, it is “tacked” or “stapled” to the undersurface of the abdominal wall as an underlay patch, and its smooth surface does, indeed, prevent adhesion formation. However, this lack of incorporation means that the mesh is difficult to salvage in the event of an infection. When infection occurs, antibiotics and drainage are provided for local wound control for several weeks, allowing a rind of granulation tissue to occur on the deep side of the mesh. When the mesh is removed, the granulation tissue is generally strong enough to prevent an evisceration. The skin can be closed over the rind (using several drains) to achieve wound closure. The resultant hernia can be repaired when it begins to expand.

### Polypropylene Mesh

Polypropylene mesh is porous, allowing for egress of fluid collections and ingrowth of fibrous tissue for improved incorporation into the tissues. Two types of polypropylene mesh are commonly used to replace full-thickness defects of the abdominal wall. Marlex mesh (C.R. Bard Corp., Cranston, RI) and Prolene mesh (U.S. Surgical Corp., Norwalk, CT) are made of the same material, but differ in how they are weaved. Of the two, Prolene mesh has a lower complication rate of such complications as enterocutaneous fistula and the need for removal after infections (6). Several studies advocate intraperitoneal placement of Prolene mesh, stating that bowel adhesions are minimized if the mesh is placed under tension to avoid wrinkles (7). In those cases when Prolene mesh becomes exposed, wound contraction of the soft tissues can often cover the exposure. The strength and good handling characteristics of Marlex were recently paired with Gore-Tex for a bilaminar mesh. The Gore-Tex is presented on its deep surface to the bowel to avoid

adhesions and fistulae, whereas the Marlex is on the superficial side to allow for improved incorporation.

### Human Acellular Dermis

Even though the skin of the hernia sac stretches and deforms as a consequence of underlying abdominal pressure, treated acellular human dermis (AlloDerm, LifeCell Corporation, Branchburg, NJ) has shown interesting characteristics when used to replace full-thickness losses of the abdominal wall (8). In animal models, it has incorporated well and shown resistance to infection. Clinically, the mesh has performed well structurally, but size limitations require that pieces of acellular dermis must be patched together. Placement intraperitoneally is possible because of a low rate of visceral adhesions; thus it may be an excellent adjunct to both direct hernia repairs and to separation of parts repairs. Hernia recurrence rates using this substance are being studied.

### Porcine Submucosa

Surgisis (Cook Surgical Co., Norwalk, CT), like acellular human dermis, is a biomaterial touted for properties of incorporation and replacement by host tissues. As with AlloDerm, the material is regarded as being more resistant to infection than prosthetic meshes. Surgisis comes in larger sheets than does AlloDerm, and has been used laparoscopically in hernia repairs. No reliable long-term data exists regarding this material.

### Fascia Lata

Decades of experience and follow-up exist for use of this autogenous biomaterial. The long-term hernia rate is 30% with this graft, although it is used in some of the most difficult and contaminated cases (8). Sheet grafts up to 22 × 12 cm in size can be harvested through long incisions along the posterolateral aspect of the leg. The donor-site complication rate, including seromas and hematomas, approaches 50%.

## Stable Soft Tissues: Lateral Abdominal Wall Defects

In contrast to midline hernias that tend to be large, lateral abdominal wall defects tend to be smaller and with good soft-tissue cover. The hernia can typically be repaired using mesh, placed either laparoscopically or by using the open technique. On occasion, for larger nonmidline hernias where there has been a mild loss of domain, a contralateral release of the *opposite* external oblique (as is described in the next section) is

performed to give the hernia contents room in the abdominal cavity.

More troublesome are the lateral bulges that are associated with some degree of denervation injury to the abdominal musculature. These bulges often occur after flank incisions for exposure of the spine and the retroperitoneum. Informed consent on operative management of these bulges is critical, because surgery generally improves but does not completely resolve the bulge. Exposure of the abdominal bulge with wide elevation of skin flaps, imbrication of the abdominal musculature while flexing the operating table to take tension off the sutures, and a large mesh overlay generally improves the bulge by only 50%.

## Unstable Soft Tissues and/or Contaminated Fields: Midline Defects

A large number of possible solutions exist for the repair of complex abdominal wall defects, as has been delineated by treatment algorithms published in the literature (9). A simplified approach to the surgical management of these problems is presented below. **Again, the solution lies in understanding that abdominal wall reconstruction is the interplay of two competing problems: how to repair the abdominal wall and how to achieve cutaneous coverage.**

When both skin and abdominal wall are deficient in the midline, the procedure of choice is abdominal wall reconstruction using bilateral myofascial rectus abdominis flaps. Referred to as “components separation” and as the “separation of parts,” the operation described by Ramirez moves the laterally displaced skin and rectus muscles toward the midline (10).

The surgical procedure is a radical removal of tissue between the medial aspects of both rectus abdominis muscles. Thin, atrophic hernia skin cover, wounds, infected mesh, draining stitch abscesses, and fistula are removed en bloc, leaving only unscarred tissue for the eventual closure (11). The releases of the external oblique muscle and fascia are performed through bilateral transverse 6-cm incisions located at the inferior border of the rib cage (Fig. 69.2). Tissues over the semilunar line are elevated by blunt dissection. The external oblique muscle and fascia are then divided under direct vision from above the rib cage to the level near the inguinal ligament. The inferior aspect of the release is completed under a small tunnel that joins the lower aspect of the midline laparotomy incision with the lateral dissection. The external oblique is then bluntly dissected off of the internal oblique, allowing the muscles to slide relative to each other. **Performed in this manner, the skin over the rectus abdominis muscle has a completely preserved blood supply.** After approximation of the fascial edges,

### Separation of Parts

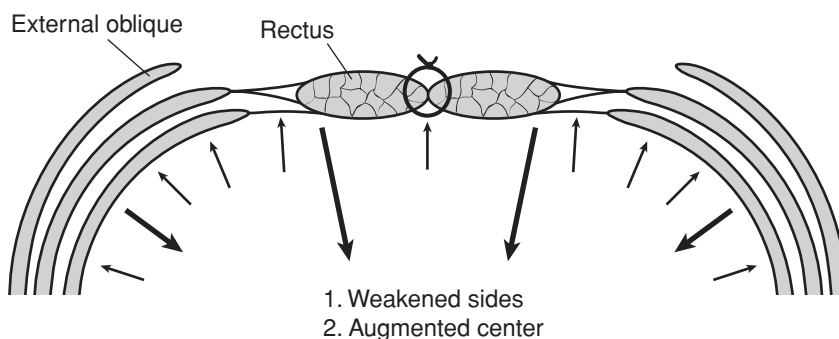


FIGURE 69.2. Diagram of forces on the abdominal wall after bilateral releases of the external oblique muscle and fascia along the semilunar lines. (Redrawn from Dumanian GA, Denham W. Comparison of repair techniques for major incisional hernias. *Am J Surg.* 2003;185:65, with permission.)

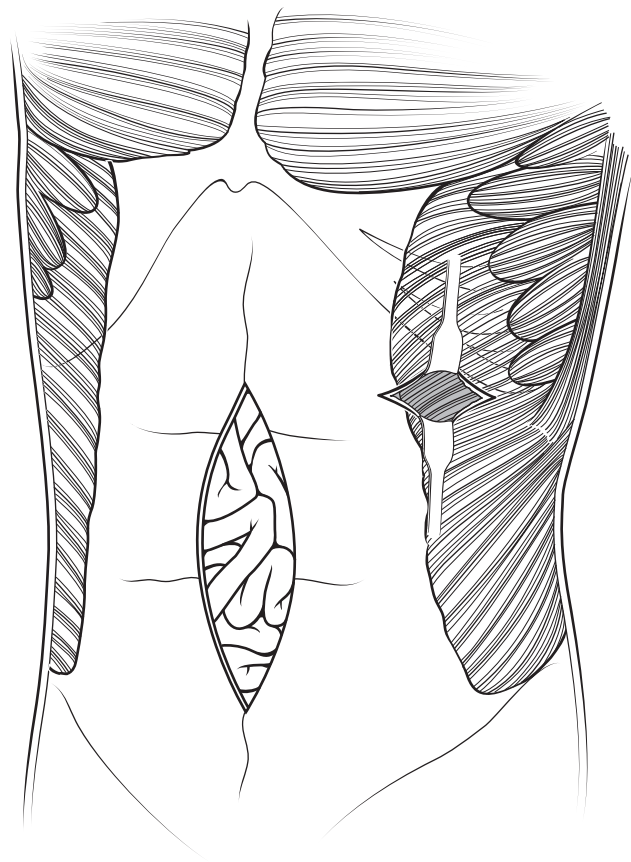


the midline closure appears identical to a standard laparotomy incision. As such, without any undermined skin flaps in the midline, mesh cannot be used in overlay fashion. However, a mesh underlay can be used to augment the midline closure and to distribute tension away from the suture line. The operation done in this manner respects the innervation and vascular anatomy of the tissues. The significantly improved soft-tissue vascularity gives the operative team the confidence to perform simultaneous bowel surgery without an increase in soft-tissue infections (12).

Rather than focus on the maximal defect size closeable with releases of the external oblique muscles, an analysis of factors that make hernias easy or difficult to close is helpful. Significant weight loss since the last laparotomy, a hernia centered on the umbilicus, no previous use of retention sutures, and an absence of previous stomas or lateral incisions all make the hernia repair more straightforward. Conversely, an upper abdominal hernia, scarred rectus muscles, stomas, and lateral incisions all make the repair more difficult. Previous mesh repairs cause the dissection to be more difficult, but the repair to be easier, because the mesh typically acts to keep the hernia down to a smaller size. By CT scan measurement, simple releases of the external oblique have allowed each of the rectus muscles to be moved 8 to 9 cm medially. By external measurements, hernias as large as 40 cm across have been closed successfully without any additional releases.

Even after external oblique release, there are times when the rectus muscles cannot be closed in the midline without undue tension. The technique, however, still brings well-vascularized skin to the midline, and this good soft-tissue cover allows the use of prosthetic mesh in clean cases, or a biologic mesh in contaminated situations. I have combined the release of the external obliques with a sheet of fascia lata in at least nine instances with no complications. The mesh is a smaller component of the repair after the releases, and the forces on the mesh are decreased because of weakened lateral musculature. Alternatively, releases of additional components of the abdominal wall, including either the transversalis fascia or the internal oblique, can be performed, but this runs the risk of significant weakness along the semilunar line. Consequently, this maneuver is to be avoided.

The infraumbilical midline hernia in the obese patient is another example of how the skin problem and the abdominal wall problem are approached separately. For these patients, a panniculectomy addresses the heavy, thick skin while simultaneously exposing the fascial edges of the hernia. Mesh can be used to patch the abdominal wall defect, but I prefer the autogenous closure provided by the separation of parts procedure (Fig. 69.3) (13). Tunnels are elevated over the semilunar lines bluntly, preserving the perforators extending from the rectus muscle to the upper skin flap. The external oblique muscles are released, and the rectus muscles can be brought to the midline in standard fashion. Increased complications, including hernia recurrence and wound complications, have been encountered with increasing body mass index.



**FIGURE 69.3.** Separation of parts procedure. Transverse incision located at the inferior aspect of the rib cage facilitates the exposure of the semilunar line. Skin vascularity is intact because of preservation of periumbilical perforators. The external oblique muscle is divided off of the rectus fascia at the anterior extent of the muscle fibers.

and biologic mesh for contaminated situations. Pedicled flaps or even free flaps are needed for larger skin replacement situations. Defects in the infraumbilical area can be treated with unilateral or even bilateral tensor fascia lata (TFL) flaps. A delay procedure is helpful to ensure tip viability of the TFL flap. The TFL flap can also be used for simultaneous structural support, but inset of the tissue when used as a flap is difficult in the inguinal area. When used for structural support, tip viability is a critical issue. **Large, supraumbilical, nonmidline skin deficits are the most problematic situations, with each case requiring a unique solution for closure.** Patients have undergone large adjacent tissue transfers with skin grafts of the donor site, pedicled myocutaneous latissimus flaps, and even free flaps on vein grafts for soft-tissue coverage in this region.

### Unstable Soft Tissues and/or Contaminated Fields: Lateral Defects

The skin issues are the most important to solve for lateral defects with poor skin, because mesh can often be used for reconstruction of the abdominal wall. For smaller skin defects, such as those that arise from tumor excisions, an assessment is made of local tissues for closure using the pinch test. Incisions along the dermatome lines, wide undermining, flexion of the patient on the operating table, and closure over drains often solves the skin problem. Prosthetic meshes are selected for clean cases,

### References

1. Dumanian GA, Denham W. Comparison of repair techniques for major incisional hernias. *Am J Surg.* 2003;185:61.
2. Sukkar SM, Dumanian GA, Szczerba SM, et al. Challenging abdominal wall defects. *Am J Surg.* 2001;181:115.
3. Dumanian GA, Llull R, Ramasastry SS, et al. Postoperative abdominal wall defects with enterocutaneous fistulae. *Am J Surg.* 1996;172:332.
4. Luijendijk RW, Hop WCJ, van den Tol MP, et al. A comparison of suture repair with mesh repair for incisional hernia. *N Engl J Med.* 2000;343:392.
5. Heniford BT, Park A, Ramshaw BJ, et al. Laparoscopic ventral and incisional hernia repair in 407 patients. *J Am Coll Surg.* 2000;190:645.

6. Stone HH, Fabian TC, Turkleson ML, et al. Management of acute full-thickness losses of the abdominal wall. *Ann Surg.* 1981;193:612.
7. Mathes SJ, Steinwald PM, Foster RD, et al. Complex abdominal wall reconstruction: a comparison of flap and mesh closure. *Ann Surg.* 2000;232:586.
8. Silverman RP, Singh NK, Li EN, et al. Restoring abdominal wall integrity in contaminated tissue-deficient wounds using autologous fascia grafts. *Plast Reconstr Surg.* 2004;113:673.
9. Rohrich RJ, Lowe JB, Hackney FL, et al. An algorithm for abdominal wall reconstruction. *Plast Reconstr Surg.* 2000;105:202.
10. Ramirez OM, Ruas E, Dellon AL. "Components separation" method for closure of abdominal wall defects: an anatomic and clinical study. *Plast Reconstr Surg.* 1990;86:519.
11. Szczerba SR, Dumanian GA. Definitive surgical treatment of infected or exposed ventral hernia mesh. *Ann Surg.* 2003;237:437.
12. Saulis AS, Dumanian GA. Periumbilical rectus abdominis perforator preservation significantly reduces superficial wound complications in "separation of parts" hernia repairs. *Plast Reconstr Surg.* 2002;109:2275.
13. Reid RR, Dumanian GA. Panniculectomy and the separation of parts hernia repair: a solution for the large infraumbilical hernia in the obese patient. *Plast Reconstr Surg.* 2005;116:1006.